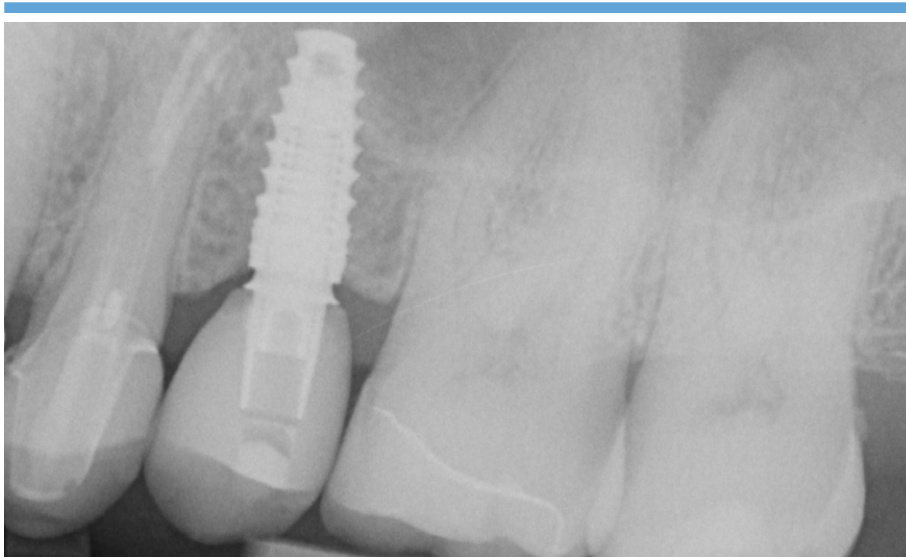
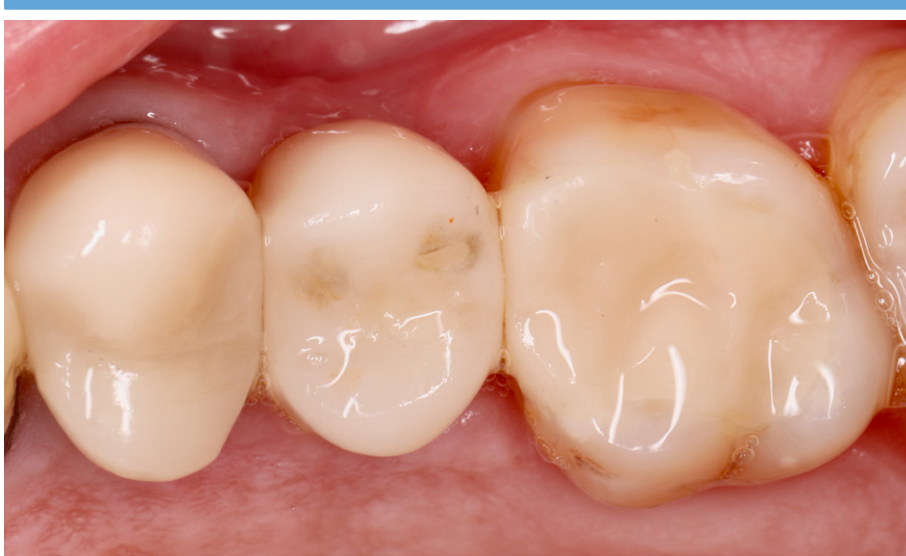

## Efficient and tissue-friendly restoration with platform switched CAMLOG® Ti Base CAD/CAM PS



**Dr. F. Hermann**  
Dentist

## CASE REPORT

## Efficient and tissue-friendly restoration with platform switched CAMLOG® Ti Base CAD/CAM PS

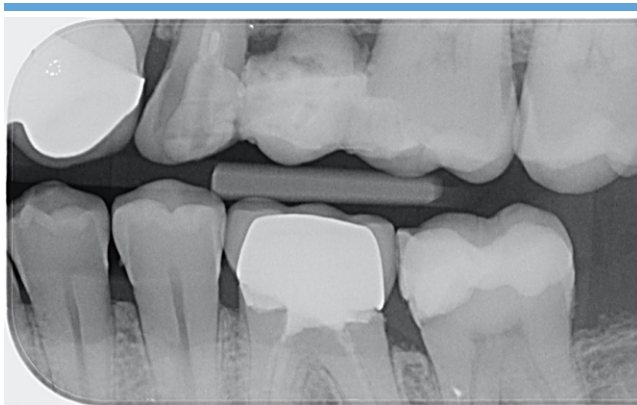» Efforts have been directed to minimize the marginal bone resorption through different approaches. One of the approaches that demonstrated positive radiographic findings in respect to crestal bone level is the utilization of the “platform-switched abutment” concept. Platform switching is defined as a protocol that includes smaller diameter restorative components that have been placed onto larger diameter implant restorative platforms – “the outer edge of the implant-abutment interface is horizontally repositioned inwardly and away from the outer edge of the implant platform” [Lazzara & Porter, 2006]. The idea behind this restorative concept is to positively influence the soft tissue dimensions and thus, the esthetics of the reconstruction and long term stability via a sealing function [Berglundh & Lindhe, 1996].

### Clinical Case

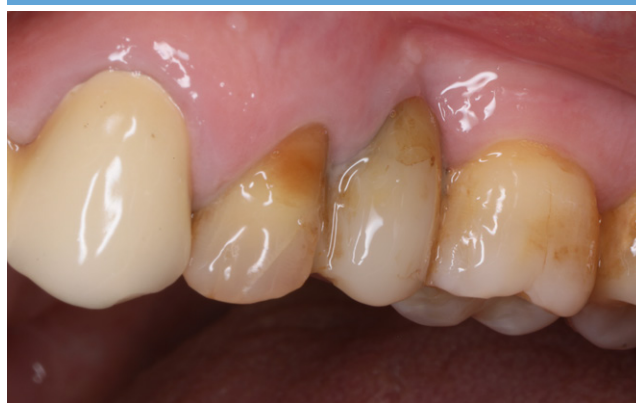The patient, 54 years old, male, non smoker and with no general diseases, presents for a routine check. Diagnostic radiographs (bite-wings, Fig. 1) show a compromised adhesively bonded bridge in the upper left posterior region (Tooth 24–26); A CBTC scan was made to orient about the surrounding structures (especially the sinus dimensions) and to plan the implant size and position. The clinical examination confirmed a well healed – but vestibularly defective – tissue structure regio 25 and a very thin gingiva type Fig. 2).

The adhesive bridge was carefully removed and a CAMLOG® PROGRESSIVE-LINE implant diameter 3.8 mm placed epicrestally, regio 25 (Fig. 4). The scan was taken 2.5 months after implant placement with a non platform switched Titanium Base CAD CAM – as the PS version was not available at that time – with a scanbody for Primescan (Sirona; software Cerec 5.1).

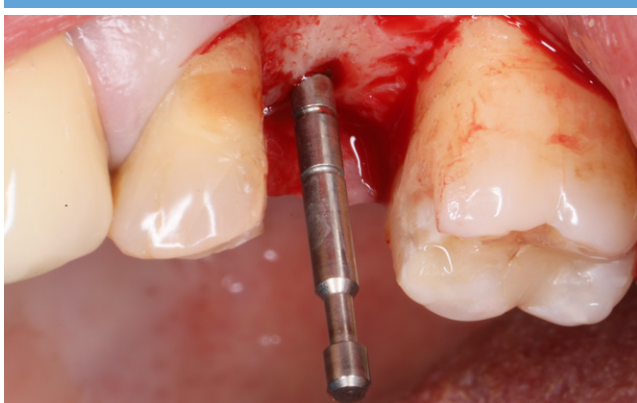As provisional the adhesive bridge was refixed with composite cement (Tetric evo flow, Ivoclar Vivadent) An intensive design process followed to build the restoration on 24 and 14 simultaneously. To restore the implant regio 25 a monolithic hybridabutment crown (emax CAD A16S, Ivoclar Vivadent) based on a platform switched titanium base was chosen (Fig. 14). The single crown on tooth 24 and the overlay on tooth 26 were made out of lithium disilicate (emax, Ivoclar Vivadent).




1. Bite wing for routine caries diagnostic. The fixation of tooth 25 has been fractured. Leading to more intensified clinical and radiological examination.



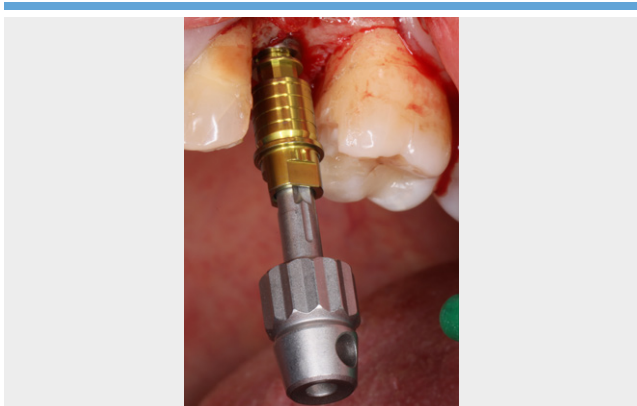
2. Lateral clinical view: The gingiva generally can be classified as thin- scalloped type. Teeth 24 and 25 showing pronounced recession and Stilian clefts. The bukkal dimension regio 25 indicates potential bukkal bony defects.



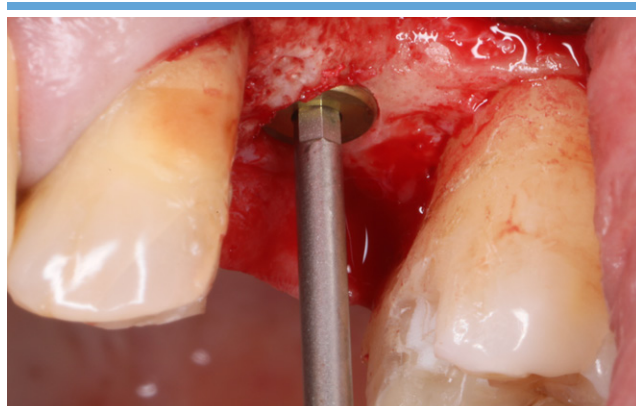3. Clinical situation after taking off the adhesive bridge and implant bed preparation after pilot drilling. The gingiva thickness is rather low and scalloped.



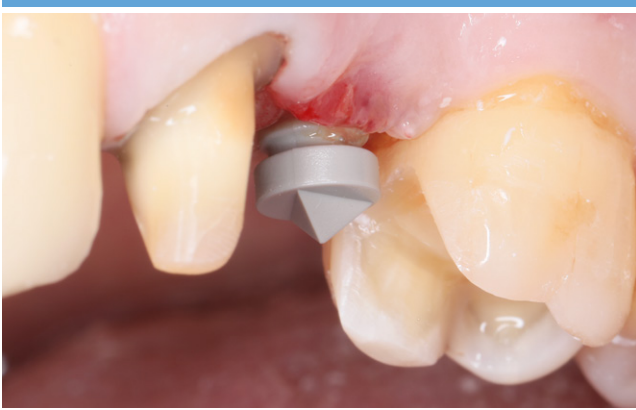4. CAMLOG® PROGRESSIVE-LINE with screw-mounted insertion post. The screw-mounted version was chosen to allow three-dimensional adaptations of the final implant position in soft bone next to the sinus.



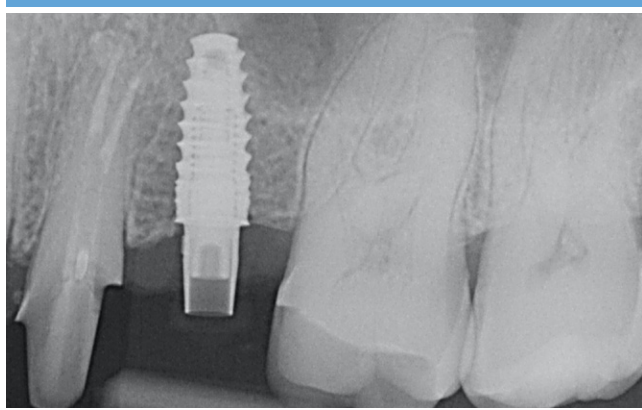
5. Insertion of implant perfectly in line with the position of other teeth in the arch and allowing for a screw retained hybrid abutment as planned. The horizontal marks on the post help to define the right gingiva height for the abutment.



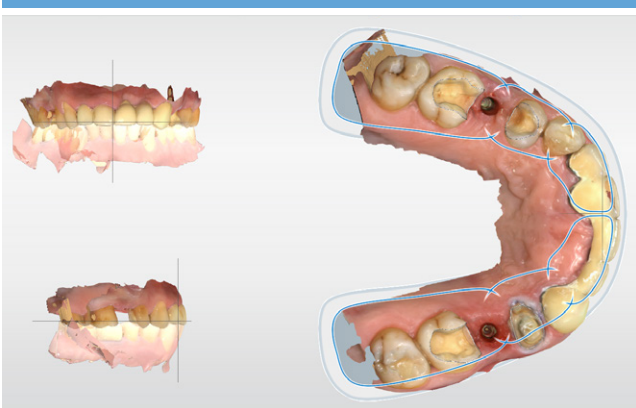
6. Inserting cover screw on equicrestally placed CAMLOG® PROGRESSIVE-LINE implant for closed healing. The vertical position of the implant considers the impact of the distance of the future abutment to the bone for optimal soft tissue development.



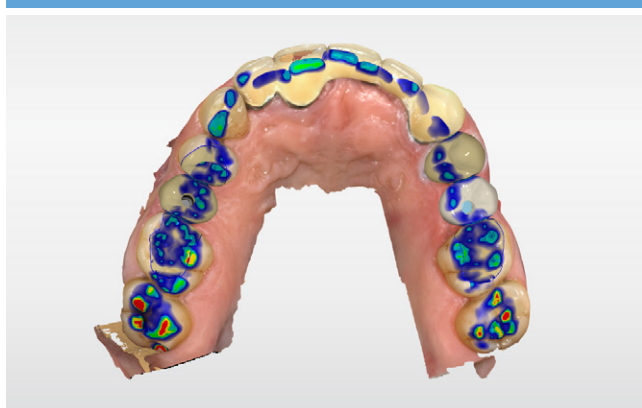
7. Implant ready to scan after a short healing period to achieve first soft tissue recovery.



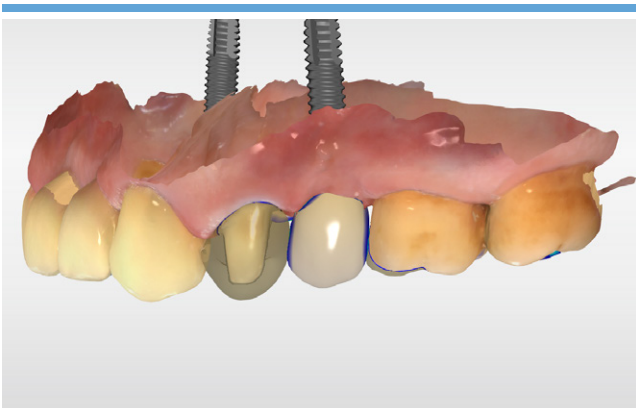
8. Radiological control with the CAMLOG® Ti Base CAD/CAM and fixed (radio-translucent) Sirona Scanbody shortly prior to the scan procedure. Note, that the Ti base PS was not available at time of scanning.



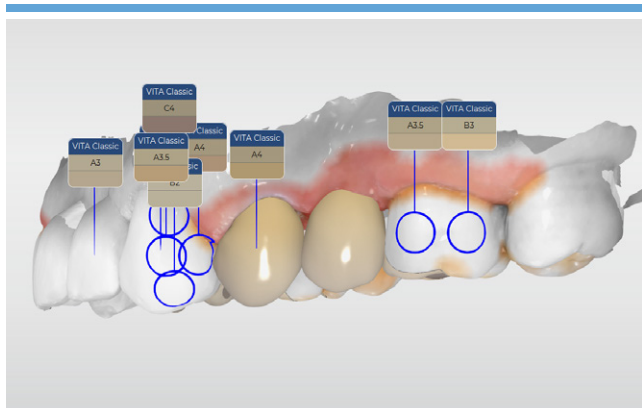
9. Adjusting of scan data and preparation for design.



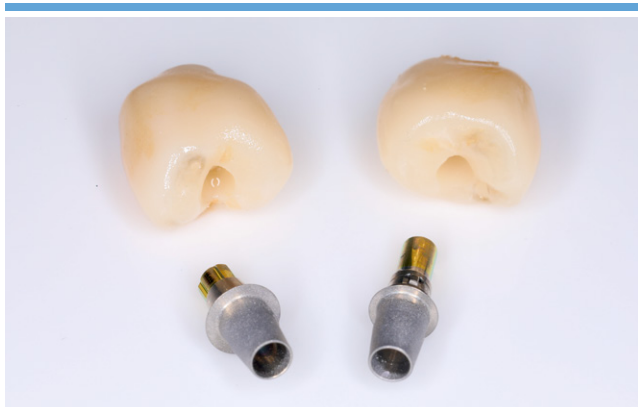10. Final design of the hybrid abutment crowns on implants regio 15 and 25, and crown for tooth 24 and inlays. Adjustment of articulation pathways.



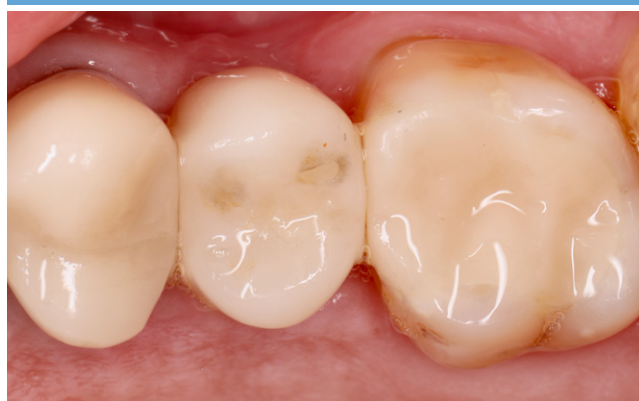11. Design of the hybrid abutment crown for tooth 25 and crown 24. Translucent visualization of restoration on tooth 24 to check available space for restorative material.



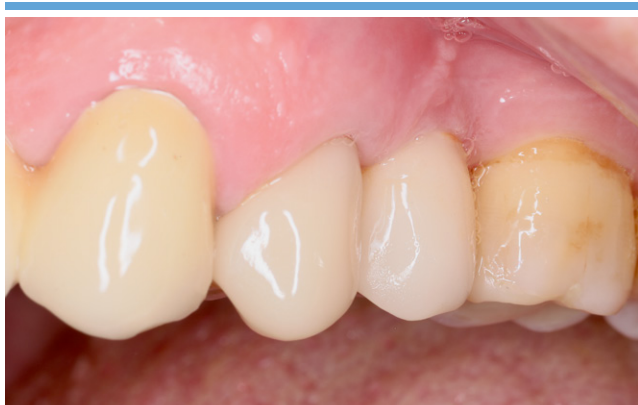12. Punctual color definition with the CEREC® integrated measurement tool digital color analysis.



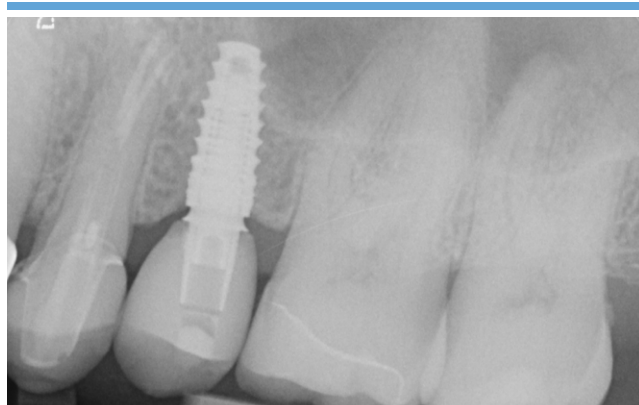
13. CAMLOG® Titanium Base CAD/CAM PS 3.8 and 3.8 with corresponding suprastructures (the upper part of the abutments has been sandblasted with 50 µm AlO<sub>2</sub>). To additionally improve the bonding of the suprastructure, the surface has later been silanized (Monobond Plus, Ivoclar Vivadent), too.



14. Occlusal view of the final full ceramic restorations in place.



15. Vestibular view of the final restoration in place after 6 month of healing.



16. Radiological control of the CAMLOG® Titanium Base CAD/CAM PS 6 months after crown placement: Ideal crestal bone preservation.

**Conclusion**

The CAMLOG® Titanium Base CAD/CAM PS is the adhesive base for customized crown abutments with platform switching. It follows the tradition of proven success of existing platform switched Camlog products and excellent crestal bone maintenance [Messias et al., 2019].

In the presented clinical case it was able to restore the gap regio 25 functionally and esthetically even under non ideal conditions. After clinical examination and using the backward planning procedure the optimal implant position and abutment could be chosen to prepare the soft tissue to be able to preserve the marginal bone in the best way: The platform switching design of the abutment and the tulip-like profile of the CAMLOG® Titanium Base CAD/CAM PS are supporting the non-surgical thickening of the soft tissue; additionally the way to directly restore the implant with the final abutment

in one session could further diminish the risk of marginal bone loss [Hermann et al., 2007].

At the same time this clinical case is an example of an optimized digital workflow in your practice. Whether in cooperation with your laboratory or as chair-side concept, the precision of the production with original parts as well as the time-efficient restoration is appealing to practice and laboratory. Depending on the laboratory equipment, the complete added value of the prosthetic restoration of the implant can be kept in-house.

Patient will honor the minimized treatment time due to the efficient workflow, performed as a single-visit-dentistry.

**References**

[1] Lazzara RJ, Porter SS. Platform switching: a new concept in implant dentistry for controlling postrestorative crestal bone levels. *Int J Periodontics Restorative Dent* 2006; 26 (1): 9–17.

[2] Berglundh T, Lindhe J. Dimensions of the peri-implant mucosa. *Biologic width revisited*. *J Clin Periodontol* 1996; 23:971-973.

[3] Messias A, Rocha S, Wagner W, Wiltfang J, Moergel M, Behrens E, Nicolau P, Guerra F. Peri-implant marginal bone loss reduction with platform-switching components: 5-Year post-loading results of an equivalence randomized clinical trial. *J Clin Periodontol*. 2019;46(6):678-687.

[4] Hermann F, Lerner H, Palti A. Factors influencing the preservation of the periimplant marginal bone. *Implant Dentistry*. 2007;16(2):165-175.

**Dr. Frederic Hermann M.Sc.**

TEAM 15 – Praxis für Zahnmedizin  
 Dr. Hermann & Partner  
 Poststrasse 15  
 CH-6300 Zug  
 Switzerland  
 Tel.: 0041 41 710 91 70  
 info@team15.ch  
 www.team15.ch

- State examination and licence to practise dentistry in 2002. 2005, he received his doctorate as Dr. med. dent. at the same university.
- From 2003 to 2007 postgraduate training in the field of implantology and perio-dontology in a private practice in Southern Germany and the completion of the curricula in these fields.
- Since 2006 diploma of the ICOI and "Certified Expert in Implantology". The recertification took place in 2012 and 2016.
- Since 2007 practising in the Team 15 - dental practice in Zug, Switzerland.
- Member of the APW, DGParo, DGI, SSO and SGI.
- 2016 Further education certificate (WBA) for oral implantology of the Swiss Dental Association.
- Founding member of the "Next(e) Generation", newly founded in 2012
- From 2013 to 2015 extra-occupational master's degree course "Clinical Dental CAD/CAM" at the University of Greifswald.
- Dr. Hermann is the author of numerous publications and an internationally active lecturer in the fields of periodontology, implantology and digital dentistry.



**Headquarters**

CAMLOG Biotechnologies GmbH | Margarethenstr. 38 | 4053 Basel | Switzerland  
Telephone +41 61 565 41 00 | Fax +41 61 565 41 01 | [info@camlog.com](mailto:info@camlog.com) | [www.biohorizonscamlog.com](http://www.biohorizonscamlog.com)

CAMLOG® is a registered trademark of Camlog Biotechnologies GmbH. It may however not be registered in all markets.  
Manufacturer of CAMLOG® products: ALTATEC GmbH | Maybachstr. 5 | 71299 Wimsheim | Germany

